

Interdisciplinarity in Complex Therapeutic Approach of Psychiatric Patients with Dysfunctional Syndrome of the Stomatognathic System

Laura Elisabeta **CHECHERITA**¹,
Lucian Ștefan **BURLEA**²,
Bogdan Petru **BULANCEA**³,
Iulian Costin **LUPU**⁴,
Liana **AMINOV**⁵,
Ioana **RUDNIC**⁶,
Tudor **HAMBURDA**⁷,
Cristina **ANTOHI**⁸,
Raluca Elena **BACIU**⁹,
Roxana Ionela **VASLIUANU**¹⁰,
Ovidiu **STAMATIN**¹¹

¹Odontology, Periodontology and Fixed Prosthesis Department, Faculty of Dental Medicine, Grigore T. Popa University of Medicine and Pharmacy, 16 Universității Street, 700115, Iasi, Romania.

²Public Health and Management, Faculty of Dental Medicine, Grigore T. Popa University of Medicine and Pharmacy, 13 Grigore Ghica Voda Street, 700259, Iasi, Romania, lucianburlea@yahoo.com

³Oral-Implantology, Dental Prostheses Technology and Removable Dentures Department, Faculty of Dental Medicine, Grigore T. Popa University of Medicine and Pharmacy, 16 Universității Street, 700115, Iasi, Romania, bulancea20@gmail.com

⁴Public Health and Management, Faculty of Dental Medicine, Grigore T. Popa University of Medicine and Pharmacy, 13 Grigore Ghica Voda Street, 700259, Iasi, Romania.

⁵Odontology, Periodontology and Fixed

Abstract: *Diseases in the maxillofacial sphere and especially the dysfunctional syndrome of the stomatognathic system have many connections and interferences with the psychiatric pathology and why not last, but not least the appearance and aesthetics that have an impact on social life and success. On the other hand, there has been a significant increase in the use of antipsychotics in recent decades. The negative impact on oral health has also increased. The ability to diagnose mental illness is essential due to the social stigma associated with these disorders and a correct differential diagnose as well. This article describes the oro-dental rehabilitation of one case, psychiatrically treated, with mandibular and maxilla missing teeth and dental destruction and prosthetic damage, temporomandibular disorders pathology due to the disbalanced occlusion and depression and anxiety, with specific medication, fixed and removable hybrid prosthesis and intra oral complex rehabilitation.*

Keywords: *fixed dental prosthesis, edentation, depression, psychiatric treatment, oro-dental rehabilitation, temporomandibular disorders.*

How to cite: Checherita, L.E., Burlea, L.S., Bulancea, B.P., Lupu, I.C., Aminov, L., Rudnic, I., Hamburda, T., Antohi, C., Baciu, R.E., Vasliuanu, R.I., & Stamatin, O. (2022). Interdisciplinarity in Complex Therapeutic Approach of Psychiatric Patients with Dysfunctional Syndrome of the Stomatognathic System. *BR AIIN, Broad Research in Artificial Intelligence and Neuroscience*, 13(1Sup1), 94-105.

<https://doi.org/10.18662/brain/13.1Sup1/305>

Decision | 15.01.2024: Based on the analysis of the authors' requests and the case information, the LUMEN Committee for Research and Publication Ethics decided the paper retraction. The retraction was based on duplicate publication.

Prosthesis Department, Faculty of Dental Medicine, Grigore T. Popa University of Medicine and Pharmacy, 16 Universităţii Street, 700115, Iasi, Romania.

⁶ Odontology, Periodontology and Fixed Prosthesis Department, Faculty of Dental Medicine, Grigore T. Popa University of Medicine and Pharmacy, 16 Universităţii Street, 700115, Iasi, Romania.

⁷ Odontology, Periodontology and Fixed Prosthesis Department, Faculty of Dental Medicine, Grigore T. Popa University of Medicine and Pharmacy, 16 Universităţii Street, 700115, Iasi, Romania.

⁸ Odontology, Periodontology and Fixed Prosthesis Department, Faculty of Dental Medicine, Grigore T. Popa University of Medicine and Pharmacy, 16 Universităţii Street, 700115, Iasi, Romania.

⁹ Oral-Implantology, Dental Prostheses Technology and Removable Dentures Department, Faculty of Dental Medicine, Grigore T. Popa University of Medicine and Pharmacy, 16 Universităţii Street, 700115, Iasi, Romania.

¹⁰ Oral-Implantology, Dental Prostheses Technology and Removable Dentures Department, Faculty of Dental Medicine, Grigore T. Popa University of Medicine and Pharmacy, 16 Universităţii Street, 700115, Iasi, Romania.

¹¹ Oral-Implantology, Dental Prostheses Technology and Removable Dentures Department, Faculty of Dental Medicine, Grigore T. Popa University of Medicine and Pharmacy, 16 Universităţii Street, 700115, Iasi, Romania.

UNITHDRAWN

Introduction

In general, for the therapeutic solution of stomatognathic dysfunctions, various and multiple means of treatment are used, which can be grouped in a prophylactic and a curative orientation.

In this phase, the prophylaxis of the dysfunctions of the stomatognathic system means in fact the prophylaxis of the dento-maxillary anomalies, of the anomalies of the muscular engrame, of the tics and vicious habits and the orthodontic adjustment must be subordinated to the gnathological functional principles (De Hert et al., 2011; Haddad & Sharma, 2007).

Most of the times, the omission of important notions of gnathology makes the orthodontic treatment to be carried out sometimes on anatomical-geometrizing or gnathological bases, forcing the growth and development factors not in functional senses, but to correspond to morphological, static patterns. Exemplification from the literature (Burlui, 2002), from this point of view, includes some morpho-geometric principles that dogmatically dominate orthodontics: mandibular incisors to make 90° with the mandibular plane and 45° with the Frankfurt plane (Tweed), the orientation of the first molars, so that the line passing through the disto-vestibular and mesio-lingual cusps meets the canine on the opposite side (Ricketts) etc (Lupu et al., 2016a; Lupu et al., 2016b). But the application in any clinical case of these formulas and the ignoring of the functional balance that is created at the level of the stomatognathic system means in fact the activation of other points generating stomatognathic dysfunctions (Feldman et al., 2004; Miodownik et al., 2011; Swager & Mcigar, 2011; Tripathi, 2005; Woods, 2003).

Clinical Case Presentation

The patient B.G., 65 years old, female, retired.

Father's history: none. Mother's history: Alzheimer's disease.

Reasons why the patient went to the dentist: the patient came to us to redo the dial bridge 3 and restore the functions of the stomatognathic system.

First, the anamnesis procedures, the medication taken, the clinical examination of the joint and muscles in the affected temporomandibular area where there was pain (Fig. 1). Then, the paraclinical examinations, CAT scan, orthopantomography and the study model (Fig. 2) were established.

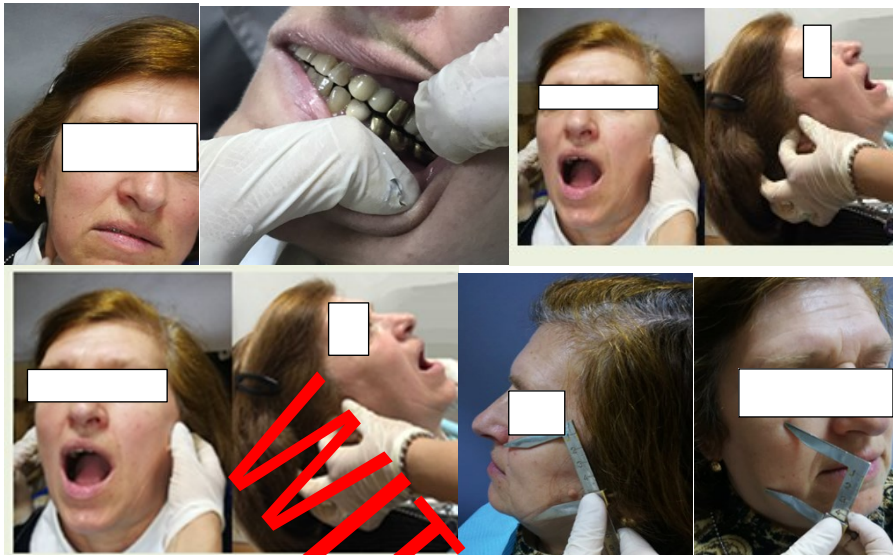

Figure 1. Clinical examination, palpation and inspection of temporomandibular joint and the symmetry aspect of the face for clinical diagnose of dysfunctional syndrome of the stomatognathic system.
Source: Authors' own conception

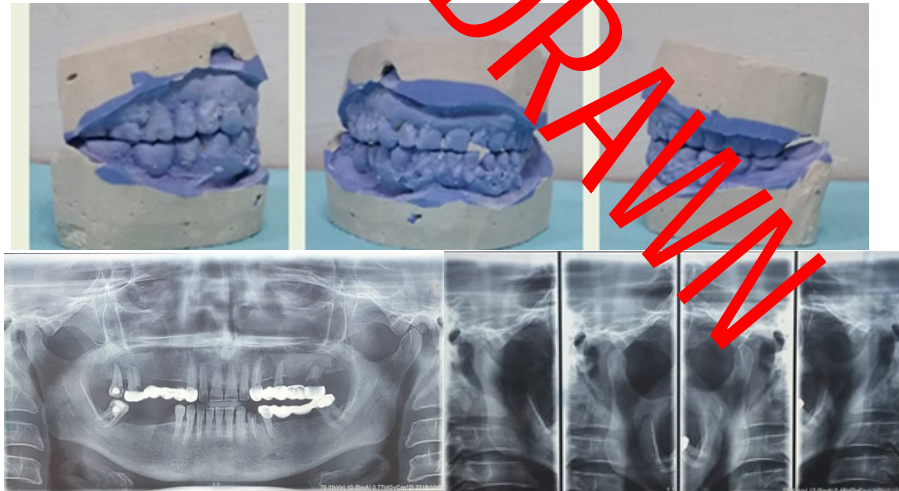


Figure 2. Paraclinical examination model study/ Orthopantomographic images and TMJ CAT scan.
Source: Authors' own conception

We can notice the working stages at the dental periodontal level and the adaptation of the fixed works and the occlusal readjustment (Fig. 3).

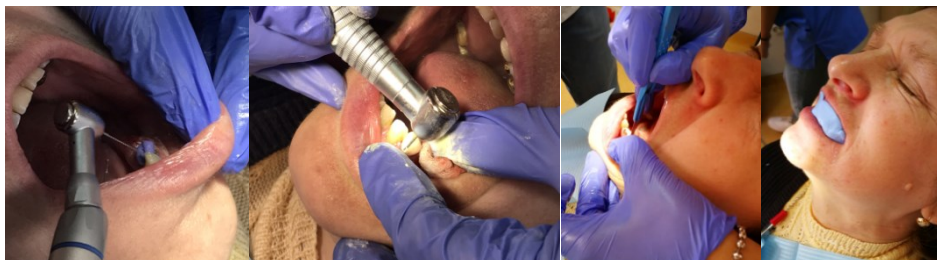


Figure 3. Pro-prosthetic preparation (Pre-prosthetic preparation): preparation for pre-prosthetic steps management of case treatment including plastic coronal reconstruction, endodontic treatment gingivectomy and preparation for uni-dental prosthesis.

Source: Authors' own conception

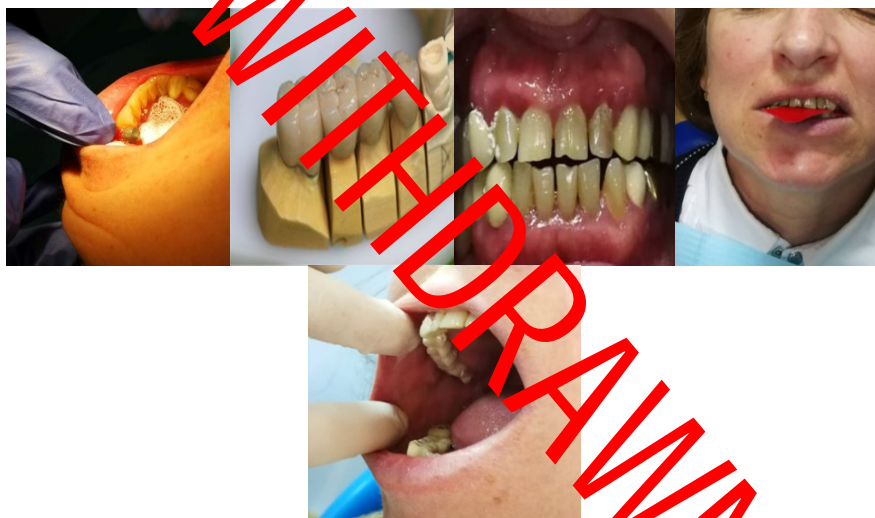

Figure 4. Adaptation and finale images of rehabilitation treatment.

Source: Authors' own conception

Discussions

From the point of view of plastic reconstructions, the restoration of the coronary volume in sub-occlusion, although it protects the obturation or the walls of the cavity from occlusal forces, limits the support area, overloads the other contact areas, realizing the conditions of a dysfunction of the whole system. For this reason, whenever the correct occlusal relief cannot be reconstituted by plastic fillings, it is good to apply inlay-onlay therapy, according to Black I, II, III, IV classes, or observing the principles of preparations and the retention means, or by means of the crowns of the

cover for the purposes of a correct restoration of the cusps and the support areas. We also mention the fact that all coronary filling materials have a lower abrasion resistance than enamel, reason for which their occlusal face depreciates shortly after application favouring the overload of other teeth and the extrusion of antagonists. We can mention that the material of the crown components, especially metal-ceramic coatings must be in accordance with the principles of realization as iatrogenesis can be created due to abrasion and fracture that can occur in case of defective and uncorrected occlusion.

Periodontal therapy can prevent the occurrence of dysfunctions of the stomatognathic system by restoring periodontal health, reducing/disappearing mobility, limiting the phenomena of dental migration and removing traumatic inclined planes.

The reduction of parafunctions, of vicious habits prevents the installation of occlusal, periodontal, articular, muscular changes that can sometimes be accentuated, taking serious and irreversible forms.

The diagnosis of altered functions must be followed carefully, followed by phonetic re-education, mastication, swallowing, and sometimes mimicry (sigmatism, unilateral mastication) swallowing by interposing the tongue between arches, orofacial dyskinesia).

Following surgery, sequelae appear that affect the main functions of the stomatognathic system. Limiting surgical sequelae, practicing conservative surgery, functional re-education after surgery, are some of the objectives of surgical prophylaxis of stomatognathic system dysfunctions.

Prosthetic treatment finds its role in the prophylaxis of stomatognathic dysfunctions by fixed prosthetic restorations, such as metal-ceramic or all-ceramic joint prosthesis that prevent the migration of teeth to the edentulous spaces, reconstituting the occlusion surfaces of the maxillary and mandibular arches shortened or interrupted by oedema. By prosthetic restoration of the edentulous arches, the occlusal tampon is reconstituted, which takes over the masticatory and swallowing forces, relieving the temporo-mandibular joint. The masticatory force increases, and, at the same time, the masticatory efficiency increases, ensuring the stomatognathic system the conditions of an optimal morphological framework for the development of functions and thus a normal trophicity of the tissues that enter its composition (Scarff & Casey, 2011; Tani et al., 2012).

The curative therapy itself- the treatment of the dysfunctions of the stomatognathic system aims for the mental rebalancing, the muscular relaxation, the treatment of the pain, the mandibula-cranial repositioning, the occlusal-articular rebalancing, using medicinal, physiotherapeutic

(Grewal et al., 2014) prosthetic methods. Within this complex therapy it is necessary a staging of the treatment phases, which will take place over more or less long periods, depending on the severity of the clinical case, for complete recovery surgical therapy is sometimes inevitable. In the same time, the necessity of a good and complete recovery can avoid the forensic aspects claims (Radu et al., 2016; Radu et al., 2017).

The treatment of dysfunctions of the stomatognathic system includes a complex of therapeutic, medicinal, and non-drug methods (prosthetic, physiotherapeutic, surgical), whose action is intricate, so that the therapy of pain, for example, from antirheumatic, muscle relaxation and mandibular repositioning cannot be precisely delimited.

Mental rebalancing of older-adult patients with stomatognathic dysfunction can be done by psycho-therapeutic and medicinal means (Burlea et al., 2010; Carausu et al., 2017).

Psychic irritation factors that lead to the maintenance of conflict states in social microclimates triggered the dysfunctional syndrome of the stomatognathic system (Arceida et al., 2012; Damian et al., 2017; Dobri et al., 2020; Munech & Hamer, 2010).

In psychic rebalancing therapy, drugs (medications) with hypnotic, sedative, tranquilizing action can be used. From this point of view, hypnotic sedatives are of great clinical utility, whose administration leads to a decrease in the activity of some areas of cortical excitation.

The mechanism of action aims to inhibit the activity of the motor neuronal chain, starting with the cortical motor neuron and ending with the neuro-muscular junction.

To depress the activity of cortical motor neurons, some medicinal substances described in psychic rebalancing therapy act: sedative hypnotics, minor tranquilizers, major tranquilizers. In addition to the above, for the purpose of a short-term motor inhibition, which would interrupt the reflex circuits, general anaesthesia can be used in the services with appropriate equipment.

Minor tranquilizers such as meprobamate, diazepam, oxazepam have also shown muscle relaxant properties. Through their action on the limbic system, they reduce psycho-emotional lability and anxiety (Damian et al., 2017).

Thus, we can mention from the literature that meprobamate is indicated for its double effect of sedation and relaxation, in cases of bruxism. Due to its mild analgesic action, which is added to the sedative, tranquilizing and relaxing ones, meprobamate is a drug with good effects in stomatognathic dysfunctions. Diazepam is administered 2 mg three times a

day, increasing the dose to 20-40 mg/day in 3-4 doses. Dose increases for both drugs can be made depending on the patient's tolerance and the severity of the case. Medazepam is a tranquilizer with a very mild sedative action, which makes it recommended for daytime use.

Medication with psychotropic drugs (sedatives, tranquilizers, anxiolytics) does not actually suppress the determining factor, but rather one of the predisposing factors. Psychotropics have the disadvantage that they keep the patient in a "psychiatric" environment that create the conditions for the installation of a drug addiction. In addition, a prolonged administration can have the following side effects: hypoxia, wakefulness disorders, side effects.

Analgesic therapy is always used concomitantly with psychotropic therapy that potentiates the action of these drugs. The treatment of pain with analgesics is only a palliative therapy because it does not suppress the cause, but only diminishes the effect, so that, after the period of action of the analgesic drug, the pain reappears. However, analgesic therapy has a recognized importance in the treatment of dysfunctions of the stomatognathic system, it being necessary to restore the patient's mental comfort, as well as to help him go through difficult periods until the cause is suppressed.

In the treatment of pain in dysfunctional syndromes of the stomatognathic system, the indication of choice is given by antirheumatic analgesics, which also have antipyretic side effects.

Subsequently, physiotherapy and kinesiotherapy (movement therapy, gymnastics) are performed, they are more and more frequently used in the treatment of stomatognathic system dysfunction (Bunui, 2002; Checherita et al., 2009; Lupu et al., 2015) to obtain a more pronounced muscle relaxation, to educate normal mandibular movement patterns, to ensure a normal joint functionality, removal of tics and parafunctions. Nevertheless, an accurate and complete therapy in such cases should look at all times to the ethical and legal aspects which are involved (Toader et al., 2017).

As we have exemplified in this case a patient with mental disorders, joint damage, rheumatism, hypertension, which occurred after the related medication in the sphere of psychiatric stomatognathic rehabilitation (Checherita et al., 2017; Cristache et al., 2019; Morley, 2002; Radulescu et al., 2020; Tatarciuc & Panaite, 2001; Zegan et al., 2017a; Zegan et al., 2017b; Zegan et al., 2018; Zegan et al., 2019), having a dissatisfaction due to the impossibility of achieving functionality but also aesthetics at stomatognathic level.

Conclusion

As shown by the rehabilitation of the patients in the study, we can conclude that drug therapy was necessary to rebalance the mental and muscular level. This is followed by the stabilization of the occlusion, providing a geometry to rearrange the clinical parameters, and restoring functionality of the stomatognathic system. The complex treatment applied provided well-being and comfort and contributed to the increase of the quality of life and the level of acceptance of the patients.

References

- Ameida, P., Johann A., Manis L., Lima A., & Grégio A. (2012). Antidepressants: Side Effects in the Mouth. In M. S. Viridi (Ed.). *Oral Health Care* (pp.113-128). <http://doi.org/10.5772/37693>
- Burlea, G., Burlea, A. M., & Manci, R. C. (2010). Prevention and intervention in speech and language therapy for the success of lexicographical acquisitions. *Revista de Cercetare și Intervenție Socială*, 30, 86- 100. <https://www.rcis.ro/ro/section1/40-volumul-302010septembrie/315-prevention-and-intervention-in-speech-and-language-therapy-for-the-success-of-lexicographical-acquisitions.html>
- Burlui, V. (2002). *Cranial-mandibular Malrelations*. Apollonia Printing House.
- Cărăușu, E. M., Dascălu, C. G., Zegan, G., Burlea, G., Lupu, I. C., & Antohe, I. (2017). The General and Oral Health Status in Older Adults from Rural Environment of Iasi County, Romania. *Revista de Cercetare și Intervenție Socială*, 59, 187-208. <https://www.rcis.ro/ro/section1/147-volumul-592017decembrie/2402-the-general-and-oral-health-status-in-older-adults-from-rural-environment-of-iasi-county-romania.html>
- Checherita, L. E., Rezus, E., Leon, M. M., Stamatina, O., & Cărăușu, E. M. (2017). Impact of Medication with Diclofenac Sodium vs. Rofenoxibum in Patients with Inflammatory Rheumatic Pathology, Prosthetic Complications and Algo-dysfunctional Syndrome. *Revista de Chimie*, 68(5), 977-981. <https://doi.org/10.37358/RC.17.5.5594>
- Cristache, C. M., Totu, E. E., Beuran, I. A., Cărăușu, E. M., Totu, T., & Burlibasa, L. (2019). Virtual Models Obtained via Intraoral Scanning as Alternated to Clinical Evaluation and beta- Hemihidrate Plaster Models. *Revista de Chimie*, 70(10), 3753-3758. <https://doi.org/10.37358/RC.19.10.7640>
- Damian, S. I., Bulgaru Iliescu, D., Rohozneanu, A., Glodeanu, A., Diac, M., David, S., & Hunea, I. (2017). The Role of Educational Measures for Juvenile Offenders in Forensic Psychiatry. *Revista Romaneasca Pentru Educatie Multidimensionala*, 9(3), 140-156. <https://lumenpublishing.com/journals/index.php/rrem/article/view/160>

- De Hert, M., Correll, C. U., Bobes, J., Cetkovich-Bakmas, M., Cohen, D., Asai, I., Detraux, J., Gautam, S., Möller, H. J., Ndeti, D. M., Newcomer, J. W., Uwakwe, R., & Leucht, S. (2011). Physical illness in patients with severe mental disorders. Prevalence, impact of medications and disparities in health care. *World Psychiatry, 10*(1), 52-77. <http://doi.org/10.1002/j.2051-5545.2011.tb00014.x>
- Dobri, M. L., Voinea, A. I., Moraru, C., Nechita, P., & Ciubara, A. (2020). Psychosis: Between Dreams and Perceptual Reality. *BRAIN. Broad Research in Artificial Intelligence and Neuroscience, 11*(3Sup1), 146-152. <https://doi.org/10.18662/brain/11.3Sup1/130>
- Feldman, P. D., Hay, L. K., Deberdt, W., Kennedy, J. S., Hutchins, D. S., Hay, D. P., Hardy, T. A., Hoffmann, V. P., Hornbuckle, K. D. V. M., & Breier, A. (2004). Retrospective cohort study of Diabetes Mellitus and antipsychotic treatment in a geriatric population in the United States. *Journal of the American Medical Association, 291*(1), 38-46. [https://doi.org/10.1001/S1552-8610\(04\)70042-0](https://doi.org/10.1001/S1552-8610(04)70042-0)
- Grewal, H., Sharma, H., Rajpal Bhatia, M. S., & Choudhary, R. (2014). Oral Health of Non-institutionalized psychiatric patients: A Dentist Perception. *Delhi Psychiatry Journal, 17*(1), 4-11. <http://www.delhipsychiatricociety.com/journal.html>
- Haddad, P. M., & Sharma, S. G. (2007). Adverse effects of atypical antipsychotics: differential risk and clinical implications. *CNS Drugs, 21*(11), 911-936. <https://doi.org/10.2165/00023210200721110-00004>
- Lupu, V. V., Ignat, A., Paduraru, G., Mihaila, I., Burlea, M., & Ciubara, A. (2015). Heterotopic gastric mucosa in the distal part of esophagus in a teenager: case report. *Medicine, 94*(42), e1722. <https://doi.org/10.1097/MD.0000000000001122>
- Lupu, V. V., Ignat, A., Paduraru, G., Ciubara, A. M., Ionice, I., Ciubara, A. B. & Burlea, M. (2016a). The study of effects regarding ingestion of corrosive substances in children. *Revista de Chimie, 67*(12), 2501-2505. <http://bch.ro/pdfRC/LUPU%20V%2012%2016.pdf>
- Lupu, V. V., Ignat, A., Ciubotariu, G., Ciubară, A., Moscalu, M., & Burlea, M. (2016b). Helicobacter pylori infection and gastroesophageal reflux in children. *Diseases of the Esophagus, 29*(8), 1007-1012. <https://doi.org/10.1111/dote.12429>
- Miodownik, C., Lerner, V., & Witztum, E. (2011). Pisa Syndrome and Laryngeal Dystonia Induced by Novel Antipsychotics. *The Israel Journal of Psychiatry and Related Sciences, 48*(3), 195-200. https://cdn.doctorsonly.co.il/2011/12/2011_3_10.pdf

- Morley, J. (2002). Macroaesthetic Elements of Smile Design. *Journal of the American Dental Association*, 132, 39–45.
<https://doi.org/10.14219/jada.archive.2001.0023>
- Muneh, J., & Hamer, A. M. (2010). Adverse Effects of Antipsychotic Medications. *American Family Physician*, 81(5), 617-622.
<https://www.aafp.org/afp/2010/0301/p617.html>
- Radu, C. C., Podila, C., Camarasan, A., Bulgaru Iliescu, D., & Perju Dumbrava, D. (2017). Ethical professional-personal model of making decisions in forensic medicine. *Romanian Journal of Legal Medicine*, 25(3), 314-316.
<https://doi.org/10.4323/rjlm.2017.314>
- Radu, C. C., & Bulgaru Iliescu, D. (2016). Claims of “uniqueness” in forensic medicine. *Romanian Journal of Legal Medicine*, 24(4), 343-345.
<https://doi.org/10.4323/rjlm.2016.343>
- Rădulescu, I. D., Ciubară, A. B., Moraru, C., Burlea, S. L., & Ciubară, A. (2020). Evaluating the Impact of Dissociation in Psychiatric Disorders. *BRAIN. Broad Research in Artificial Intelligence and Neuroscience*, 11(3Sup1), 163-174.
<https://doi.org/10.18662/brain/11.3Sup1/132>
- Scarff, J. R., & Casey, D. A. (2011). Newer or atypical antipsychotic agents: a review. *P & T: a peer-reviewed journal for formulary management*, 36(12), 832–838.
- Swager, L. W. M., & Morgan, S. K. (2017). Psychotropic induced dry mouth: Don't overlook this potentially serious side effect. *Current Psychiatry*, 10(12), 54-58.
https://cdn.mdedge.com/files/s3fs_public/Document/September-2017/1012CP_MedPsych.pdf
- Tani, H., Uchida, H., Suzuki, T. et al. (2012). Dental conditions in patients with schizophrenia: A large-scale multi-site survey. *BMC Oral Health*, 12, 32.
<https://doi.org/10.1186/1472-6831-12-32>
- Tatarciuc, M. S., & Panaite, S. (2001). *Tehnologia protezelor unidentare*. Casa de Editura Venus.
- Tripathi, K. D. (2005). *Essentials of Medical Pharmacology* (4th ed.). Jaypee Brothers Medical Publishers.
- Toader, E., Balan, G. G., Iliescu, D. B., & Perju Dumbrava, D. (2017). Ethical and legal medicine aspects related to hepatic encephalopathy. *Romanian Journal of Legal Medicine*, 25(1), 125-127. <https://doi.org/10.4323/rjlm.2017.125>
- Woods, S. W. (2003). Chlorpromazine equivalent doses for the newer atypical antipsychotics. *The Journal of Clinical Psychiatry*, 64(6), 663-667.
<https://doi.org/10.4088/jcp.v64n0607>
- Zegan, G., Moscu, M., Cernei, E. R., Cărauşu, E. M., & Sodor Botezatu, A. (2019a). Antimicrobial Effect of Drug Incorporated Nanoparticles against Oral Pathogens. *Revista de Chimie*, 70(12), 4445-4447.
<https://doi.org/10.37358/RC.19.12.7774>

- Zegan, G., Cărașu, E. M., Golovcencu, L., Botezatu, A.S., Cernei, E. R., & Anistoroaei, D. (2017). Nanoparticles Deposition on Mini-implants for Osseo-integration and Antibacterial Properties Improvement. *Revista de Chimie*, 68(12), 2929-2931. <https://doi.org/10.37358/RC.17.12.6009>
- Zegan G., Golovcencu, L., Cernei, E. R., Cărașu, E. M., & Anistoroaei, D. (2018). Structural and Morphological Characteristics of Hybrid Nanomaterials Type Ascorbic Acid-hydrotalcite Used for Stimulating Salivary Secretion. *Revista de Chimie*, 69(5), 1244-1246. <https://doi.org/10.37358/RC.18.5.6299>
- Zegan G., Cernei, E. R., Cărașu, E. M., Golovcencu, L., & Anistoroaei D. (2019b). Structural Characteristics of Drug Intercalated Hydrotalcites Used in Dental Medicine. *Revista de Chimie*, 70(4), 1215-1217. <https://doi.org/10.37358/RC.19.4.7094>

WITHDRAWN